

## NOTES

### LruA and LruB Antibodies in Sera of Humans with Leptospirosis<sup>∇</sup>

Ashutosh Verma,<sup>1†</sup> S. R. Rathinam,<sup>2</sup> C. Gowri Priya,<sup>3</sup> V. R. Muthukkaruppan,<sup>3</sup>  
 Brian Stevenson,<sup>4</sup> and John F. Timoney<sup>1\*</sup>

M. H. Gluck Equine Research Center, Department of Veterinary Science, University of Kentucky, Lexington, Kentucky 40546<sup>1</sup>; Uvea Clinic, Aravind Eye Hospital, No. 1, Anna Nagar, Madurai 625 020, Tamil Nadu, India<sup>2</sup>; Aravind Medical Research Foundation, No. 1, Anna Nagar, Madurai 625 020, Tamil Nadu, India<sup>3</sup>; and Department of Microbiology, Immunology and Molecular Genetics, University of Kentucky, College of Medicine, Lexington, Kentucky 40536<sup>4</sup>

Received 17 May 2007/Returned for modification 10 August 2007/Accepted 1 April 2008

**Uveitis can be a serious complication of leptospirosis. Previous studies indicated that the leptospiral lipoproteins LruA and LruB are expressed in the eyes of uveitic horses and that antibodies directed against those proteins show in vitro cross-reactivity with components of equine lens, ciliary body, and/or retina. We now demonstrate that sera from a significant proportion of humans who have leptospiral uveitis also contain antibodies against LruA and LruB. Different categories of nonleptospiral uveitis and autoimmune uveitis were also screened; patients diagnosed with Fuchs uveitis or Behçet's syndrome produced antibodies that cross-reacted with LruA and LruB, suggesting similarities of the autoimmune responses in those diseases with those of leptospiral uveitis.**

Varied degrees of ocular complications have been reported for human and equine leptospirosis. Infection with *Leptospira* spp. is the most common cause of equine recurrent uveitis (12, 13), which is characterized by an initial uveitic episode followed weeks to months later by regularly recurring episodes of intraocular inflammation (10). Human leptospiral uveitis has been reported in various areas of the world, including the region around the city of Madurai in southern India (6, 17, 22, 23). The prolonged symptom-free period between leptospiral infection and clinical onset of an ocular condition, the clinical/morphological similarity of different uveitic entities, and the protean manifestations of leptospiral uveitis all make a definitive diagnosis difficult for the ophthalmologist. Due to the current lack of any specific diagnostic assay, presumptive diagnosis is made on the basis of a past exposure to a potentially contaminated environment, the exclusion of other etiologies, and a positive microscopic agglutination test (MAT) (20).

Although MAT is the gold standard for diagnosis of leptospirosis, its usefulness as a reliable laboratory test for leptospiral uveitis needs to be evaluated in various settings and conditions. Several recombinant proteins have been proposed as potential candidates for improving the serodiagnosis of leptospirosis in humans and animals (2, 11, 18). Recently, two leptospiral lipoproteins, LruA and LruB, were associated with equine leptospiral uveitis (25). These antigens elicited very strong immunoglobulin G (IgG) and IgA responses in uveitic

eyes. Moreover, LruA and LruB antibodies reacted with proteins in equine ocular tissue extracts, implicating autoimmune aspects with leptospiral uveitis (25). The encoding genes, *lruA* and *lruB*, are present in infectious *Leptospira interrogans* but not in nonpathogenic *Leptospira biflexa*. In the current study we examined the association of LruA and LruB with human leptospiral uveitis by measuring serum antibody levels in leptospiral uveitis patients and comparing these with the levels in patients affected with other forms of uveitis.

Uveitis patients attending the Uvea Clinic, Aravind Eye Hospital, Madurai, India, were recruited for the study after they had provided informed consent and after approval of the study by the Institutional Review Board of Aravind Eye Hospital. Clinical diagnosis of leptospiral uveitis was based on a detailed clinical history, an extensive review of systems, a complete ophthalmic examination, and laboratory and ancillary tests. After clinical diagnosis, MAT was performed following standard procedures (7), using 19 leptospiral serovars obtained from the Royal Tropical Institute, The Netherlands (19). As the sensitivity of the MAT is low, a set of clinical diagnostic predictors, identified using samples from more than 500 seropositive leptospiral uveitis and 4,800 nonleptospiral uveitis cases by multiple logistic regression analysis (21), was used to identify seronegative leptospiral uveitis cases. Acute, anterior or pan, nongranulomatous uveitis with hypopyon, disc edema, vasculitis, and vitreous exudates were taken as inclusion criteria. (8, 21, 23). In addition, idiopathic uveitis and other entities associated with HLA B27, leprosy, sarcoidosis, and tuberculosis were carefully evaluated for exclusion from the leptospiral uveitis group.

Identification, cloning, and expression of recombinant LruA and LruB have been described previously (25). Briefly, following PCR amplification of chromosomal DNA of *L. interrogans* serovar Pomona type kennewicki (JEN4) using gene-specific

\* Corresponding author. Mailing address: 325 M. H. Gluck Equine Research Center, University of Kentucky, Lexington, KY 40546. Phone: (859) 257-4757, ext. 81106. Fax: (859) 257-5619. E-mail: jtimoney@uky.edu.

† Present address: Department of Microbiology, Immunology and Molecular Genetics, University of Kentucky, College of Medicine, Lexington, KY 40536.

<sup>∇</sup> Published ahead of print on 9 April 2008.

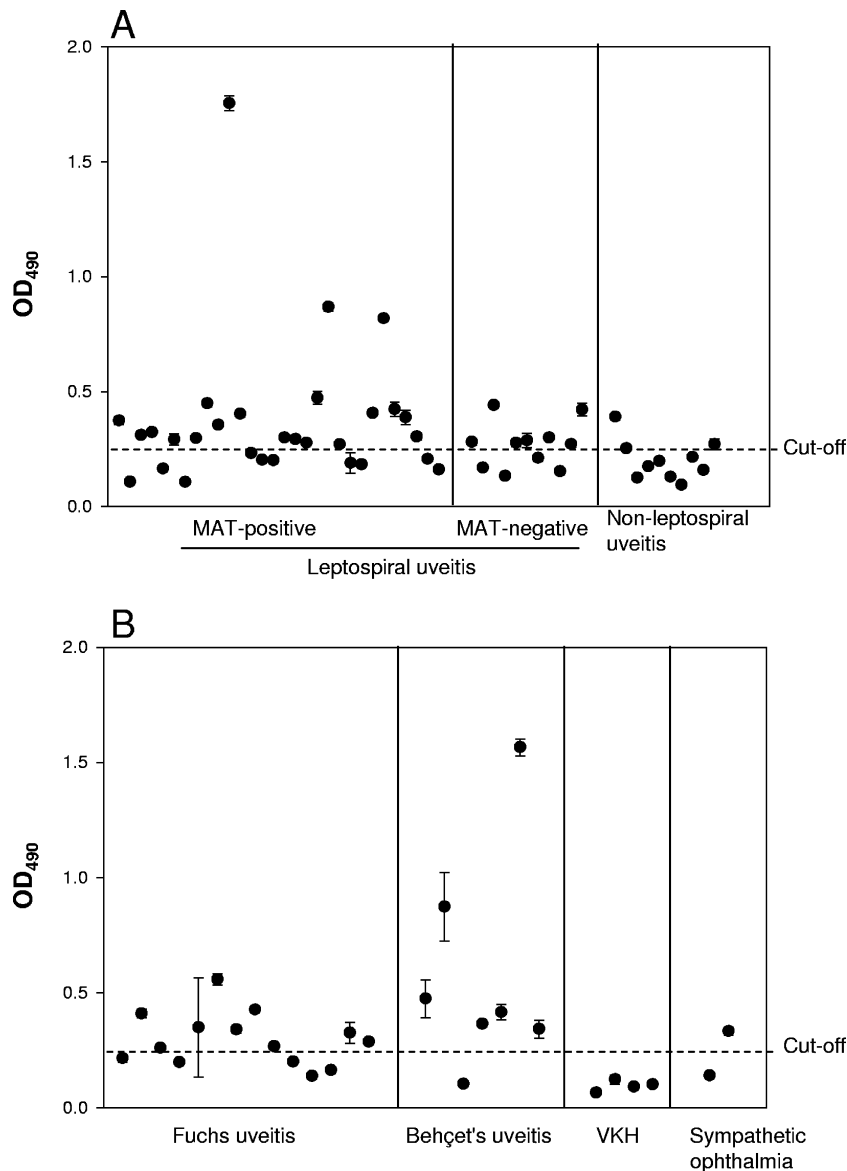


FIG. 1. LruA serum antibody levels in patients with leptospiral uveitis and in controls. (A) LruA serum antibody levels in patients with MAT-positive leptospiral uveitis ( $n = 30$ ), MAT-negative leptospiral uveitis ( $n = 11$ ), and nonleptospiral uveitis ( $n = 10$ ). (B) LruA serum antibody levels in patients with Fuchs uveitis ( $n = 14$ ), Behçet's uveitis ( $n = 7$ ), VKH ( $n = 4$ ), and sympathetic ophthalmia ( $n = 2$ ). The cutoff value was the mean plus two SD of the absorbance values (optical density at 490 nm [OD<sub>490</sub>]) of sera from healthy controls. The error bars indicate SD. Serum samples are charted in the same order as in Fig. 2.

primers, amplicons were inserted into pET-15b (Novagen, Madison, WI). Recombinant plasmids were transformed into *Escherichia coli* BL21(DE3) (Novagen, Madison, WI), and recombinant His-tagged proteins were isolated and their purity tested as previously described (25). Enzyme-linked immunosorbent assay (ELISA) plates were coated with recombinant LruA and LruB (50 ng/well) in bicarbonate buffer (pH 9.6) by incubation overnight at 4°C. The next day, after washing (Immunowash; Bio-Rad) in phosphate-buffered saline–Tween 20, plates were blocked with 5% dry milk in phosphate-buffered saline–Tween 20 for 1 h at 37°C. Diluted serum samples (1:100) were added to each well, incubated for 1 h at 37°C, and then washed to remove unbound material. Bound IgG was detected using horseradish peroxidase-conjugated antibodies

to human IgG (Sigma, St. Louis, MO; 1:4,000). Plates were developed using *ortho*-phenylene diamine (Sigma). All samples were analyzed in triplicate. Several control wells without antigen, serum, or horseradish peroxidase conjugate were included to detect nonspecific binding. Sera from five healthy (nonuveitic, MAT-negative) population controls were used as negative controls. The cutoff value was defined as the mean absorbance value for population controls plus two standard deviations (SD). Data obtained from ELISA were analyzed by the Mann-Whitney Wilcoxon test. Correlation between LruA and LruB antibody levels in sera of leptospiral uveitis patients was performed using Excel X software (Microsoft Corporation). A  $P$  value of  $<0.05$  was considered significant.

Thirty patients with clinical evidence of leptospiral uveitis

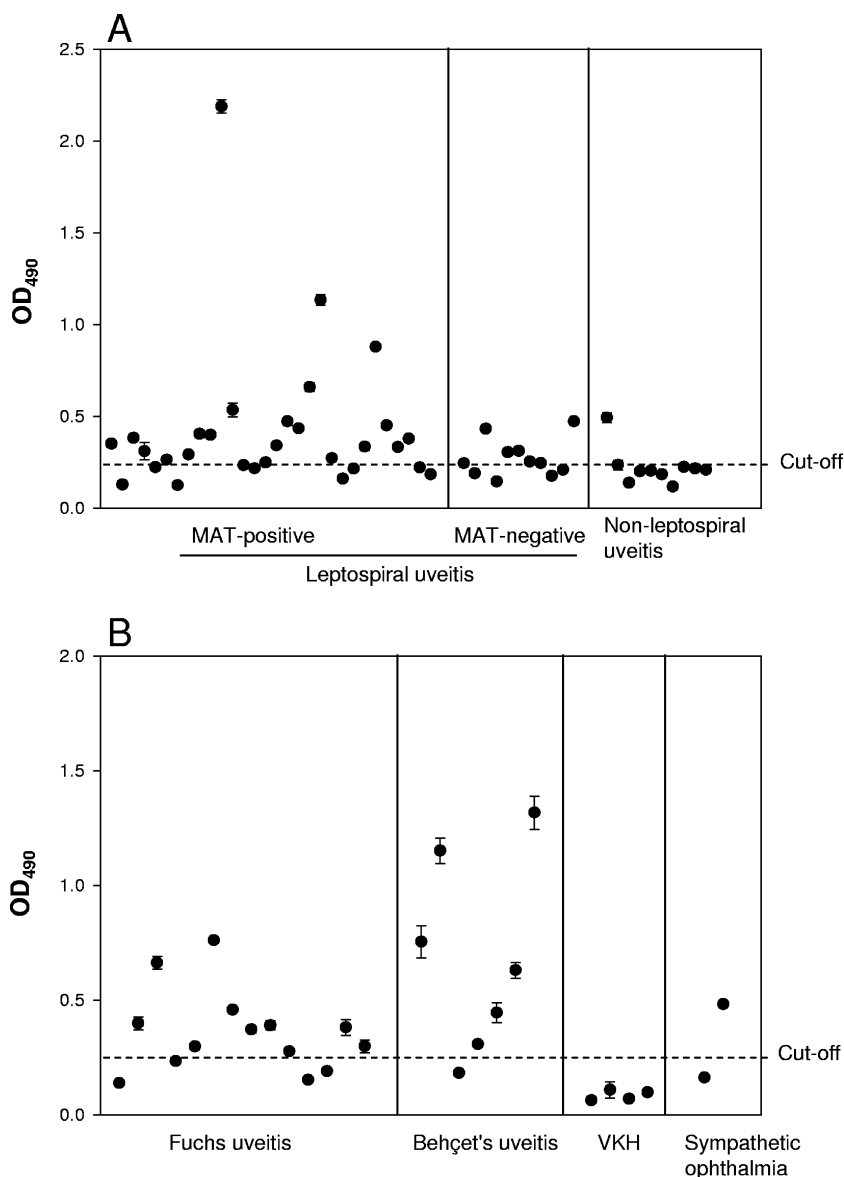


FIG. 2. LruB serum antibody levels in patients with leptospiral uveitis and in controls. (A) LruB serum antibody levels in patients with MAT-positive leptospiral uveitis ( $n = 30$ ), MAT-negative leptospiral uveitis ( $n = 11$ ), and nonleptospiral uveitis ( $n = 10$ ). (B) LruB serum antibody levels in patients with Fuchs uveitis ( $n = 14$ ), Behçet's uveitis ( $n = 7$ ), VKH ( $n = 4$ ), and sympathetic ophthalmia ( $n = 2$ ). The cutoff value was the mean plus two SD of the absorbance values (optical density at 490 nm [OD<sub>490</sub>]) of sera from healthy controls. The error bars indicate SD. Serum samples are charted in the same order as in Fig. 1.

and a positive MAT reaction were selected for the study and designated the “MAT-positive leptospiral uveitis” group. At the time of presentation at Aravind Eye Hospital’s Uvea Clinic, no member of this group had any symptom of acute leptospiral infection. Eleven patients fulfilling the specific clinical criteria for leptospiral uveitis but seronegative by MAT comprised the “MAT-negative leptospiral uveitis” group. In the MAT-positive leptospiral uveitis group, 20 out of 30 (67%) were seropositive in the LruA-specific ELISA (Fig. 1A). Similarly, 21 out of 30 (70%) MAT-positive leptospiral uveitis cases were seroreactive for LruB (Fig. 2A). Interestingly, in the MAT-negative leptospiral group, 64% were seropositive for both antigens (Fig. 1A and 2A). Together, 66% and 68% of

sera from all leptospiral uveitis cases (MAT positive and MAT negative) contained significant levels of antibodies for LruA and LruB, respectively.

Leptospiral uveitis shares several clinical features with other uveitic entities, such as Behçet’s uveitis, brucellosis, Fuchs heterochromic iridocyclitis, HLA B27-related uveitis, sarcoidosis, syphilis, tuberculosis, and other related forms of uveitis. For example, hypopyon can be seen in young patients suffering from leptospiral uveitis, Behçet’s uveitis, and HLA B27-related uveitis (23). Similarly, the vitreous inflammatory reaction is a common feature of leptospiral uveitis, acute retinal necrosis, endogenous endophthalmitis, and toxoplasmosis (23).

To evaluate the effectiveness of LruA and LruB in differen-

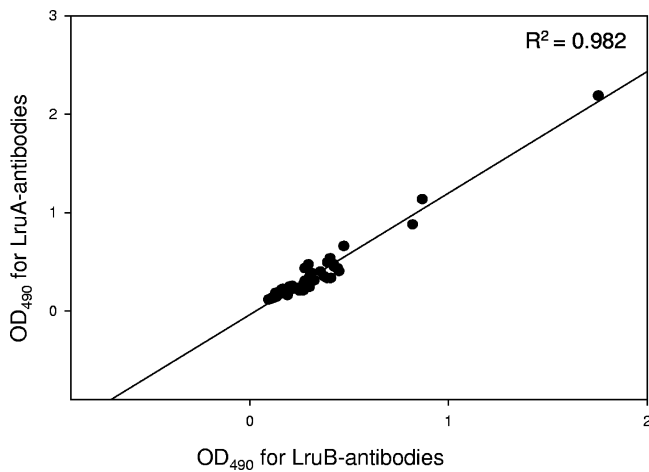


FIG. 3. Correlation between levels (ELISA optical density at 490 nm [OD<sub>490</sub>]) of LruA antibodies and LruB antibodies in sera from patients with leptospiral and nonleptospiral uveitis ( $r^2 = 0.982$ ).

tiating leptospiral uveitis from other uveitic entities, several control groups were examined. Ten nonleptospiral uveitis patients comprised one set of controls. This group included patients with nonleptospiral uveitic entities, such as viral uveitis, sarcoidosis, and idiopathic uveitis. In this group, 2 and 1 of a total of 10 cases were seropositive to LruA and LruB, respectively (Fig. 1A and 2A). Patients with leptospiral uveitis had significantly higher LruA- and LruB-specific antibody levels than those with nonleptospiral uveitis ( $P < 0.01$  for both). In addition, LruA and LruB antibody levels in sera from patients with MAT-positive leptospiral uveitis, MAT-negative leptospiral uveitis, and nonleptospiral uveitis patients were highly correlated ( $r^2 = 0.982$ ) (Fig. 3).

Another set of controls comprised 27 patients with autoimmune uveitis diagnosed with Fuchs uveitis (14 cases), Behçet's uveitis (7 cases), Vogt Koyanagi Harada syndrome (VKH) (4 cases), and sympathetic ophthalmia (2 cases). Unexpectedly, for Fuchs uveitis, 64% and 71% were positive for LruA (Fig. 1B) and LruB (Fig. 2B), respectively. In Behçet's uveitis, 86% of cases were positive for both antigens (Fig. 1B and 2B). Fuchs uveitis is a chronic, unilateral iridocyclitis characterized by iris heterochromia that leads to the development of abnormal uveal pigment with chronic low-grade inflammation, eventually causing iris atrophy and secondary glaucoma (4). Behçet's uveitis, a component of Behçet's syndrome, is seen as a chronic inflammation of the uvea (1). Both Fuchs uveitis and Behçet's syndrome are believed to be autoimmune diseases (1, 5, 9, 14, 15, 24). Recent studies have shown that antibodies directed against LruA and LruB cross-react with several equine ocular proteins, including lenticular, ciliary, and retinal components, which share significant sequence homology with their human counterparts (A. Verma and J. F. Timoney, unpublished data). In combination, the observations on reactivity of sera from patients with different uveitic syndromes suggest that a limited repertoire of epitopes participate in autoimmune-mediated uveitis. Further investigations into this phenomenon are ongoing, including characterization of autoantigens recognized by LruA- and LruB-directed antibodies and by sera of patients with Fuchs and Behçet's uveitis.

No serum from four patients with VKH and one of two sera from patients with sympathetic ophthalmia yielded a positive reaction with either antigen (Fig. 1B and 2B). Although the sample sizes were too small for the results to be conclusive, the absence of reactivity with LruA or LruB suggests possible differences in autoantigens involved in the pathogenesis of these conditions.

An association between a significant antibody level against LruA and LruB and the presence of cataract was evident, irrespective of the group of uveitis patients. Of the 23 patients with cataract, 15 (67%) were seropositive for LruA and 14 (61%) were positive for LruB (Table 1). All groups with cataract except the leptospiral uveitis group had significant levels of LruA and LruB antibody irrespective of type of uveitis ( $P < 0.05$ ). Since there was only one patient in the leptospiral uveitis group, it was not included. Cataract is a common complication of uveitis in human and equine patients but usually remains stable after initial inflammation is controlled. Spontaneous absorption of cataract, though seen mainly in traumatic cataract, congenital rubella, and age-related leaking Morgagnian cataract (3, 16), has also been reported in a small number of leptospiral uveitis patients (22).

In conclusion, antibodies directed against LruA and LruB were found in >65% of sera from MAT-positive and MAT-negative patients with leptospiral uveitis. These patients were from different districts of the southern Indian state of Tamil Nadu, and information on infecting serovars is not known. Although the sequences of genes encoding LruA and LruB are known to be highly conserved among the pathogenic serovars of *L. interrogans* (25), the absence of significant serum levels of LruA and LruB antibodies in some clinical cases may be due to antigenic differences in the proteins expressed by the endemic local serovars.

LruA and LruB antibody levels may be of value in differentiating leptospiral uveitis from idiopathic uveitis but, intriguingly, not from Fuchs and Behçet's autoimmune uveitis. Cataract is a feature common to both Fuchs and leptospiral uveitis. Moreover, Behçet's uveitis clinically mimics leptospiral uveitis. The high levels of antibodies that are cross-reactive with LruA and LruB in patients with Fuchs and Behçet's uveitis and the strong association between LruA and LruB antibody levels and presence of cataract in different groups of uveitis patients suggest that identification of reactive host pro-

TABLE 1. Association of cataract with elevated levels of LruA and LruB antibodies in sera of patients with cataract

Group	No. (%) of patients:		
	With cataract	Positive <sup>a</sup> for:	
		LruA antibodies	LruB antibodies
Leptospiral uveitis	1	1 (100)	1 (100)
Fuchs uveitis	14	9 (64)	10 (71)
Nonleptospiral uveitis	3	2 (67)	1 (33)
Ungrouped cataract cases	5	3 (60)	2 (40)
Total	23	15 (67)	14 (61)

<sup>a</sup> Sera showing an antigen-specific optical density at 490 nm of greater than the mean optical density at 490 nm for healthy population controls plus two SD were considered positive.

teins will be helpful in understanding the pathogenesis of several different ocular pathologies.

A. Verma was funded by a Paul Mellon Fellowship in Equine Studies. This work was supported by the Keeneland Association and grants from Indian Council of Medical Research, New Delhi, India, and the Aravind Medical Research Foundation, Madurai, Tamil Nadu, India.

We thank Angela Schoergendorfer for help with statistical analysis and P. Ramadass for helpful suggestions.

#### REFERENCES

1. Al-Otaibi, L. M., S. R. Porter, and T. W. J. Poate. 2005. Behçet's disease: a review. *J. Dent. Res.* **84**:209–222.
2. Artiushin, S., J. F. Timoney, J. Nally, and A. Verma. 2004. Host-inducible immunogenic sphingomyelinase-like protein, Lk73.5, of *Leptospira interrogans*. *Infect. Immun.* **72**:742–749.
3. Boger, W. P., R. A. Petersen, and R. M. Robb. 1981. Spontaneous absorption of the lens in the congenital rubella syndrome. *Arch. Ophthalmol.* **99**:433–434.
4. Bonfioli, A. A., A. L. Curi, and F. Orefice. 2005. Fuchs' heterochromic cyclitis. *Semin. Ophthalmol.* **20**:143–146.
5. Chowers, I., E. Zamir, E. Banin, and S. Merin. 2000. Retinitis pigmentosa associated with Fuch's heterochromic uveitis. *Arch. Ophthalmol.* **118**:800–802.
6. Chu, K. M., R. Rathinam, P. Namperumalsamy, and D. Dean. 1998. Identification of *Leptospira* species in the pathogenesis of uveitis and determination of clinical ocular characteristics in south India. *J. Infect. Dis.* **177**:1314–1321.
7. Cole, J. R., C. R. Sulzer, Jr., and A. R. Pursell. 1973. Improved microtechnique for the leptospiral microscopic agglutination test. *Appl. Microbiol.* **25**:976–980.
8. Dana, M. R. 2002. Leptospirosis, p. 273–277. In C. S. Foster and A. T. Vitale (ed.), *Diagnosis and treatment of uveitis*. W. B. Saunders, Philadelphia, PA.
9. Delunardo, F., F. Conti, P. Margutti, C. Alessandri, R. Priori, A. Siracusano, R. Riganò, E. Profumo, G. Valesini, M. Sorice, and E. Ortona. 2006. Identification and characterization of the carboxy-terminal region of Sip-1, a novel autoantigen in Behçet's disease. *Arthritis Res. Ther.* **8**:R71.
10. Dwyer, A. E., and B. C. Gilger. 2005. Equine recurrent uveitis, p. 285–322. In B. C. Gilger (ed.), *Equine ophthalmology*. W.B. Saunders Co., Philadelphia, PA.
11. Flannery, B., D. Costa, F. P. Carvalho, H. Guerreiro, J. Matsunaga, E. D. Da Silva, A. G. P. Ferreira, L. W. Riley, M. G. Reis, D. A. Haake, and A. I. Ko. 2001. Evaluation of recombinant *Leptospira* antigen-based enzyme-linked immunosorbent assays for the serodiagnosis of leptospirosis. *J. Clin. Microbiol.* **39**:3303–3310.
12. Halliwell, R. E., T. A. Brim, M. T. Hines, D. Wolf, and F. H. White. 1985. Studies on equine recurrent uveitis. II. The role of infection with *Leptospira interrogans* serovar Pomona. *Curr. Eye Res.* **4**:1033–1040.
13. Hartskeerl, R. A., M. G. Goris, S. Brem, P. Meyer, H. Kopp, H. Gerhards, and B. Wollanke. 2004. Classification of leptospira from the eyes of horses suffering from recurrent uveitis. *J. Vet. Med. B* **51**:110–115.
14. La Hey, E., L. Broersma, R. van der Gaag, G. S. Baarsma, A. Rothova, and A. Kijlstra. 1993. Does autoimmunity to S-antigen play a role in Fuchs' heterochromic cyclitis? *Br. J. Ophthalmol.* **77**:436–439.
15. Lu, Y., P. Ye, S. Chen, E. M. Tan, and E. K. L. Chan. 2005. Identification of kinectin as a novel Behçet's disease autoantigen. *Arthritis Res. Ther.* **7**:R1133–R1139.
16. Marlow, S. B. 1952. Spontaneous absorption of cataract. *Trans. Am. Ophthalmol. Soc.* **50**:283–293.
17. Martins, M. G., K. T. F. Matos, M. V. da Silva, and M. T. de Abreu. 1998. Ocular manifestations in the acute phase of leptospirosis. *Ocul. Immunol. Inflamm.* **6**:75–79.
18. Palaniappan, R. U. M., Y. F. Chang, F. Hassan, S. P. McDonough, M. Pough, S. C. Barr, K. W. Simpson, H. O. Mohammed, S. Shin, P. McDonough, R. L. Zuerner, J. Qu, and B. Roe. 2004. Expression of leptospiral immunoglobulin-like protein by *Leptospira interrogans* and evaluation of its diagnostic potential in a kinetic ELISA. *Med. Microbiol.* **53**:975–984.
19. Priya, C. G., K. Bhavani, S. R. Rathinam, and V. R. Muthukkaruppan. 2003. Identification and evaluation of LPS antigen for serodiagnosis of uveitis associated with leptospirosis. *J. Med. Microbiol.* **52**:667–673.
20. Rathinam, S. R. 2005. Ocular manifestations of leptospirosis. *J. Postgrad. Med.* **51**:189–194.
21. Rathinam, S. R. 2006. Studies on clinical presentation, diagnosis and management of infectious uveitis with reference to leptospirosis. Ph.D. dissertation. Tamilnadu Dr. M. G. R. Medical University, Chennai, India.
22. Rathinam, S. R., P. Namperumalsamy, and E. T. Cunningham, Jr. 2000. Spontaneous cataract absorption in patients with leptospiral uveitis. *Br. J. Ophthalmol.* **84**:1135–1141.
23. Rathinam, S. R., S. Rathnam, S. Selvaraj, D. Dean, R. A. Nozik, and P. Namperumalsamy. 1997. Uveitis associated with an epidemic outbreak of leptospirosis. *Am. J. Ophthalmol.* **124**:71–79.
24. van der Gaag, R., L. Broersma, A. Rothova, S. Baarsma, and A. Kijlstra. 1989. Immunity to a corneal antigen in Fuchs' heterochromic cyclitis patients. *Investig. Ophthalmol. Vis. Sci.* **30**:443–448.
25. Verma, A., S. Artiushin, J. Matsunaga, D. A. Haake, and J. F. Timoney. 2005. LruA and LruB, novel lipoproteins of pathogenic *Leptospira interrogans* associated with equine recurrent uveitis. *Infect. Immun.* **73**:7259–7266.